

Clinical Cancer Research



Mind the Gap: Potential for Rebounds during Antiangiogenic Treatment Breaks

John M.L. Ebos and Roberto Pili

Clin Cancer Res 2012;18:3719-3721. Published OnlineFirst June 7, 2012.

Updated version Access the most recent version of this article at:
doi:[10.1158/1078-0432.CCR-12-1459](https://doi.org/10.1158/1078-0432.CCR-12-1459)

Supplementary Material Access the most recent supplemental material at:
<http://clincancerres.aacrjournals.org/content/suppl/2012/07/10/1078-0432.CCR-12-1459.DC1.html>

Cited Articles This article cites by 12 articles, 7 of which you can access for free at:
<http://clincancerres.aacrjournals.org/content/18/14/3719.full.html#ref-list-1>

E-mail alerts [Sign up to receive free email-alerts](#) related to this article or journal.

Reprints and Subscriptions To order reprints of this article or to subscribe to the journal, contact the AACR Publications Department at pubs@aacr.org.

Permissions To request permission to re-use all or part of this article, contact the AACR Publications Department at permissions@aacr.org.

CCR Translations

Commentary on Griffioen et al., p. 3961

Mind the Gap: Potential for Rebounds during Antiangiogenic Treatment Breaks

John M.L. Ebos and Roberto Pili

VEGF pathway inhibitors have shown benefits in many cancers, yet many (often controversial) questions remain about whether vascular and tumor regrowth can occur when therapy is stopped. Marked increases in endothelial cell proliferation could play a role in putative rebounds, potentially influencing overall efficacy, dosing schedules, and presurgical intervention strategies. *Clin Cancer Res*; 18(14): 3719–21. ©2012 AACR.

In this issue of *Clinical Cancer Research*, Griffioen and colleagues (1) retrospectively analyzed data from 3 clinical trials in which patients with renal cell carcinoma (RCC) were treated with VEGF pathway inhibitors prior to cytoreductive nephrectomy. Histologic examination of kidney tumors revealed several signs of overall therapeutic benefit, including decreases in VEGF pathway–related genes, such as VEGF receptors 1 and 2 (VEGFR-1/2), angiopoietin 1 and 2 (ANG-1/2), and placental growth factor, among others, as well as suppression of tumoral microvessel density. However, perhaps most significant is their observation that proliferation of tumor vascular endothelial cells (EC) increased after stopping treatment and continued to increase during prolonged "drug-free" gaps before surgery. Importantly, this proliferation was found after the discontinuation of the VEGFR tyrosine kinase inhibitor (VEGFR TKI) sunitinib, but not the VEGF-neutralizing antibody bevacizumab. Despite some limitations due to the small sample size and the reliance only on retrospective data analysis from separate trials, the study results from Griffioen and colleagues raise several pertinent questions about VEGFR TKI therapy in the presurgical setting, including whether prolonged break periods can lead to rebounds in vascular and tumor growth and potentially offset the post-surgical benefits of treatment.

Antiangiogenic therapies have achieved objective clinical success over the past decade with U.S. Food and Drug Administration approval of 5 VEGF pathway inhibitors in 10 different disease types, but benefits have been more muted than expected, and progression-free survival has not always translated into benefits in overall survival. However, and potentially due to specific genetic and/or epigenetic alterations of the von Hippel–Lindau gene, clear-cell RCC

may be unique among disease types, as VEGF pathway inhibitors (particularly the VEGFR TKIs) have dramatically altered the practice of treating metastatic disease. As a result, several phase III trials are now under way, examining whether similar therapeutic benefits can also apply to early-stage disease, including in the perioperative settings, such as with adjuvant (postsurgical) and neoadjuvant (presurgical) treatments. For the latter, although cytoreductive nephrectomy has itself represented a potential benefit to systemic (metastatic) disease, there are several theoretical advantages for including antiangiogenic therapy in this setting. Among them is that by down-staging primary tumors, the chances of nephron-sparing surgery may be enhanced. Furthermore, data collected from pretreated surgical specimens could provide physicians with molecular and pathologic feedback about drug responses, which in turn could be used to assess drug sensitivity and/or give clues about intrinsic resistance, both of which could inform later (postsurgical) treatment choices for metastatic disease. Finally, treatment of localized disease with a systemic therapy could blunt growth not only of "known" primary tumors but also of occult "unknown" micrometastatic disease, thus potentially prolonging (or even eliminating) disease recurrence after surgery.

However, potential disadvantages to perioperative antiangiogenic therapy have also been raised, and the study by Griffioen and colleagues highlights that rebounds in vascular proliferation could be one example (Fig. 1). Previously, preclinical models have shown that halting antiangiogenic therapy could lead to rapid vascular regrowth (2), and some studies have shown tumors can quickly grow after therapy is stopped (3, 4). Furthermore, clinical examples of tumor "flares" have been noted during drug holidays or upon treatment discontinuation (5), and isolated case reports show that occult metastatic disease, if missed during cytoreductive sunitinib therapy prior to nephrectomy, can rapidly regrow during prolonged drug washout periods prior to surgery (6). Potentially related to these findings, tumor and stromal changes in response to VEGF pathway inhibition may also increase invasive and metastatic behavior in certain instances (7). Importantly, one driver of this behavior could be tumor hypoxia (a consequence of

Authors' Affiliation: Genitourinary Program, Roswell Park Cancer Institute, Buffalo, New York

Corresponding Authors: John M.L. Ebos, Roswell Park Cancer Institute, Elm and Carlton Streets, Buffalo, NY 14263-0001. Phone: 716-845-3117; Fax: 716-845-8232; E-mail: John.Ebos@RoswellPark.org; or Roberto Pili. E-mail: Roberto.Pili@RoswellPark.org

doi: 10.1158/1078-0432.CCR-12-1459

©2012 American Association for Cancer Research.

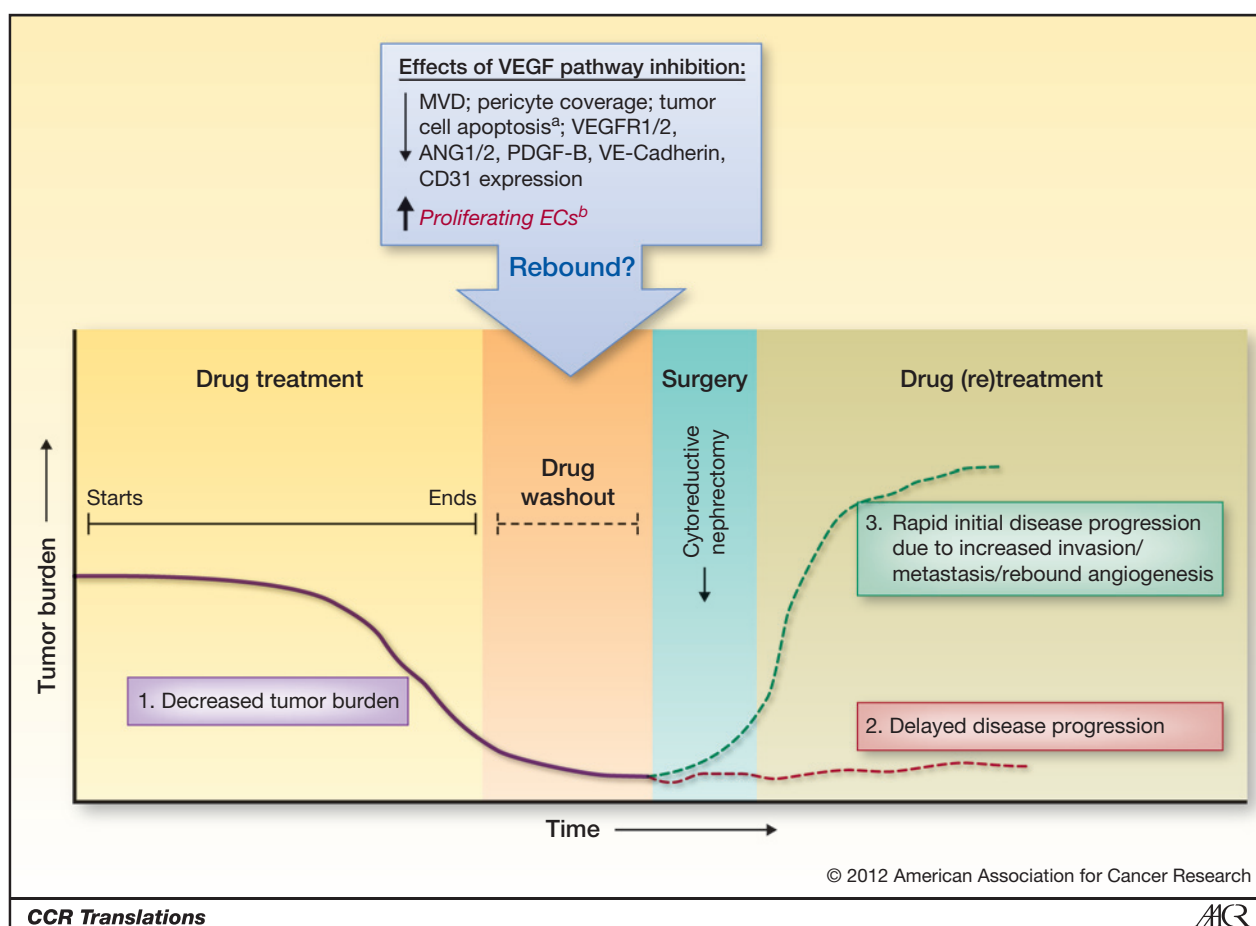


Figure 1. Tumor vascular rebound following cessation of VEGFR TKI therapy in RCC patients and possible implications: 1. presurgical tumor response (purple line); 2. delayed disease recurrence and increased progression free survival (red line); and 3. potential for increased growth of occult disease or selection of a resistant and/or more aggressive tumor phenotype (green line).^aBevacizumab only; ^bSunitinib only. MVD, microvessel density; VE-cadherin, vascular endothelial cadherin.

antiangiogenic therapy), which could fuel epithelial-to-mesenchymal transition changes and play a role in eventual drug-resistance phenotypes (8). However, evidence of tumor vascular rebounds or increased growth following treatment discontinuation has not been confirmed in all cases (9), and many questions remain, including whether this phenomenon occurs with all types of VEGF pathway inhibitors, whether it depends on disease and disease stage, and whether a clinical impact (if real) can be determined for patients.

Several indicators show that disease stage could play a critical role not only in how tumors respond to VEGF pathway inhibition but also in how they respond when treatment stops. Because preclinical studies have mostly focused on models of localized tumor growth and clinical studies have mainly looked at established metastatic disease, it is possible that drug effects in one may not predict for effects in the other, either on or off treatment (7). For this reason, it is unclear whether, in the study by Griffioen and colleagues, the proliferative endothelial cells after sunitinib treatment reflect a change expected to be seen in metastatic disease. A recent retrospective examination of

sunitinib in patients with metastatic RCC yielded evidence that tumors did indeed regrow when therapy was discontinued at a rate similar to that before intervention, but growth rates were not increased in an accelerated manner (10). Also important, differences in inhibition strategies could be significant to whether rebounds are related to one drug or another. Although regrowth has been noted during break periods with sunitinib-treated patients, preclinical (11) and clinical (12) studies with VEGF-neutralizing antibodies have not shown increases in regrowth after treatment discontinuation, a difference that Griffioen and colleagues confirm in the presurgical setting with bevacizumab. Although several reasons could explain this observation, including longer drug half-life for antibodies (which can last several weeks) and target specificity [receptor TKIs, such as sunitinib, have multiple targets in addition to VEGFRs, including c-kit, platelet-derived growth factor receptor (PDGFR), and others; ref. 7], it may account for some differences seen in the clinical success with both types of agents, either alone or with chemotherapy.

Of the many questions that remain about the clinical relevance of changes in presurgical RCC tumors following

sunitinib treatment scheduling, perhaps it is the potential clinical impact that is the most significant. Subsequent studies with larger patient samples will be required to determine whether sunitinib-induced increases in tumoral ECs correlate with rapid vascularization and tumor regrowth and should address whether postsurgical outcomes could be affected. Furthermore, prospective studies, rather than retrospective analyses, will need to be done that coincide with relevant perioperative preclinical studies to monitor the impact of long versus short treatment breaks and their effect prior to or immediately following nephrectomy. Finally, tumor heterogeneity remains a challenge not only for tumor genetic profiling and biomarker discovery but also for the histologic assessment of vasculature changes upon antiangiogenic therapies. In the near future, perhaps

technically improved and less expensive noninvasive imaging modalities will contribute to achieving a personalized approach to antiangiogenics, in which optimal dose, schedule, duration, and disease setting will be tailored to each patient.

Disclosure of Potential Conflicts of Interest

R. Pili: research funding, Regeneron; consultant, Pfizer, Regeneron, Genentech. No potential conflicts of interest were disclosed by the other author.

Authors' Contributions

Conception and design: J.M.L. Ebos, R. Pili

Writing, review, and/or revision of the manuscript: J.M.L. Ebos, R. Pili

Received May 16, 2012; accepted May 30, 2012; published OnlineFirst June 7, 2012.

References

- Griffioen AW, Mans LA, de Graaf AMA, Nowak-Sliwinska P, de Hoog C, de Jong T, et al. Rapid angiogenesis onset after discontinuation of sunitinib treatment of renal cell carcinoma patients. *Clin Cancer Res* 2012;18:3961–71.
- Mancuso MR, Davis R, Norberg SM, O'Brien S, Sennino B, Nakahara T, et al. Rapid vascular regrowth in tumors after reversal of VEGF inhibition. *J Clin Invest* 2006;116:2610–21.
- Levashova Z, Backer M, Hamby CV, Pizzonia J, Backer JM, Blankenberg FG. Molecular imaging of changes in the prevalence of vascular endothelial growth factor receptor in sunitinib-treated murine mammary tumors. *J Nucl Med* 2010;51:959–66.
- Nagengast WB, Lub-de Hooge MN, Oosting SF, den Dunnen WF, Wamders FJ, Brouwers AH, et al. VEGF-PET imaging is a non-invasive biomarker showing differential changes in the tumor during sunitinib treatment. *Cancer Res* 2010;71:143–53.
- Wolter P, Beuselink B, Pans S, Schöffski P. Flare-up: an often unreported phenomenon nevertheless familiar to oncologists prescribing tyrosine kinase inhibitors. *Acta Oncol* 2009;48:621–4.
- Petrelli F, Cabiddu M, Carpo M, Ghilardi M, Barni S. Progression of intramedullary metastasis during perioperative cessation of sunitinib. *Nat Rev Urol* 2010;7:634–7.
- Ebos JM, Kerbel RS. Antiangiogenic therapy: impact on invasion, disease progression, and metastasis. *Nat Rev Clin Oncol* 2011;8:210–21.
- Hammers HJ, Verheul HM, Salumbides B, Sharma R, Rudek M, Jaspers J, et al. Reversible epithelial to mesenchymal transition and acquired resistance to sunitinib in patients with renal cell carcinoma: evidence from a xenograft study. *Mol Cancer Ther* 2010;9:1525–35.
- di Tomaso E, Snuderl M, Kamoun WS, Duda DG, Auluck PK, Fazlollahi L, et al. Glioblastoma recurrence after cediranib therapy in patients: lack of "rebound" revascularization as mode of escape. *Cancer Res* 2011;71:19–28.
- Stein WD, Wilkerson J, Kim ST, Huang X, Motzer RJ, Fojo AT, et al. Analyzing the pivotal trial that compared sunitinib and IFN- α in renal cell carcinoma, using a method that assesses tumor regression and growth. *Clin Cancer Res* 2012;18:2374–81.
- Bagri A, Berry L, Gunter B, Singh M, Kasman I, Damico LA, et al. Effects of anti-VEGF treatment duration on tumor growth, tumor regrowth, and treatment efficacy. *Clin Cancer Res* 2010;16:3887–900.
- Miles D, Harbeck N, Escudier B, Hurwitz H, Saltz L, Van Cutsem E, et al. Disease course patterns after discontinuation of bevacizumab: pooled analysis of randomized phase III trials. *J Clin Oncol* 2011;29:83–8.